

Navigating the transition from hospital to rehabilitation in HIV: a complex case

Katty Mayre-Chilton¹, Mary Tait², Erin McDowell², Maria Tomassini²,
Josh Hutcheson², Asterios Lotsios¹

¹ Mildmay Hospital, London

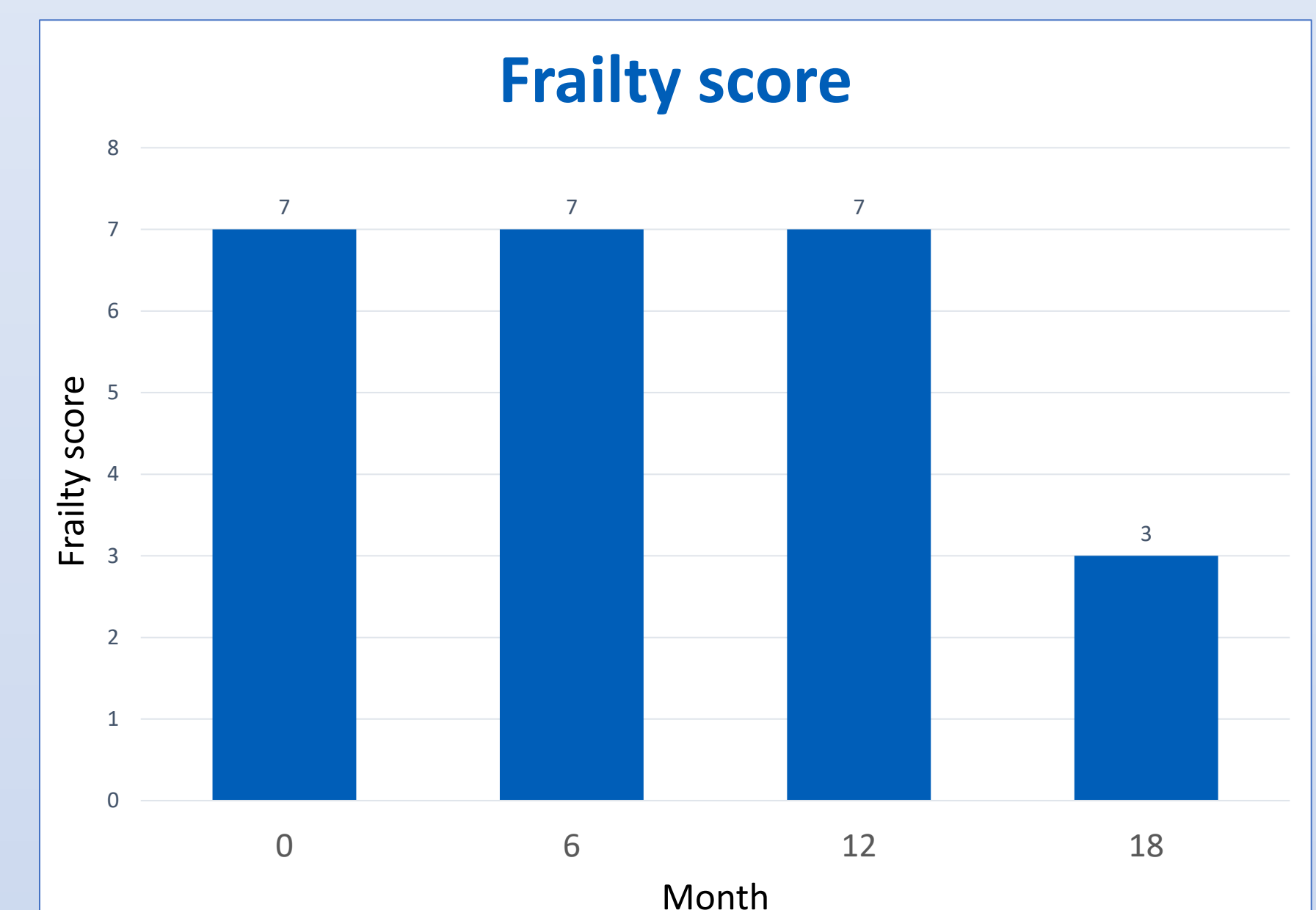
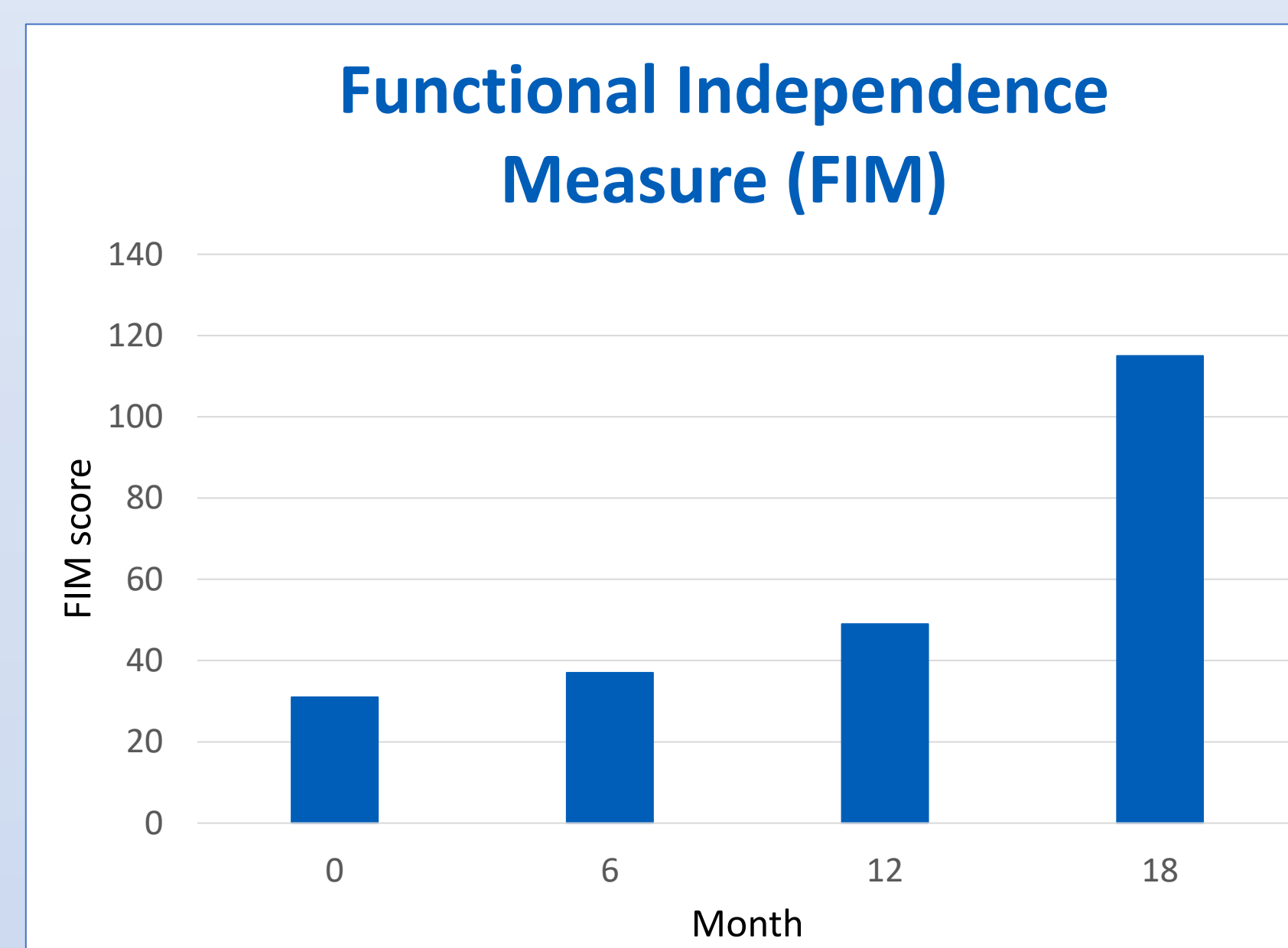
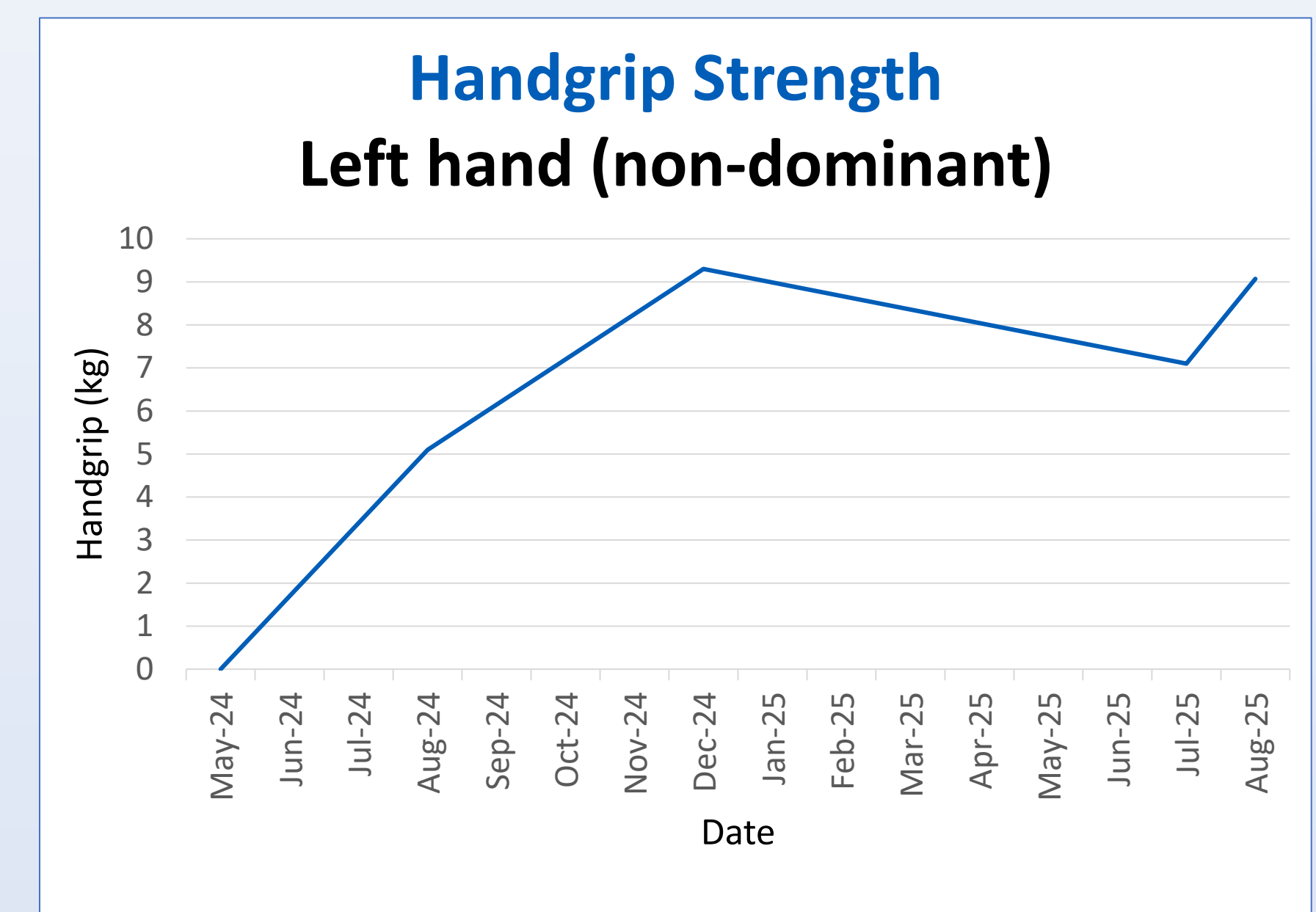
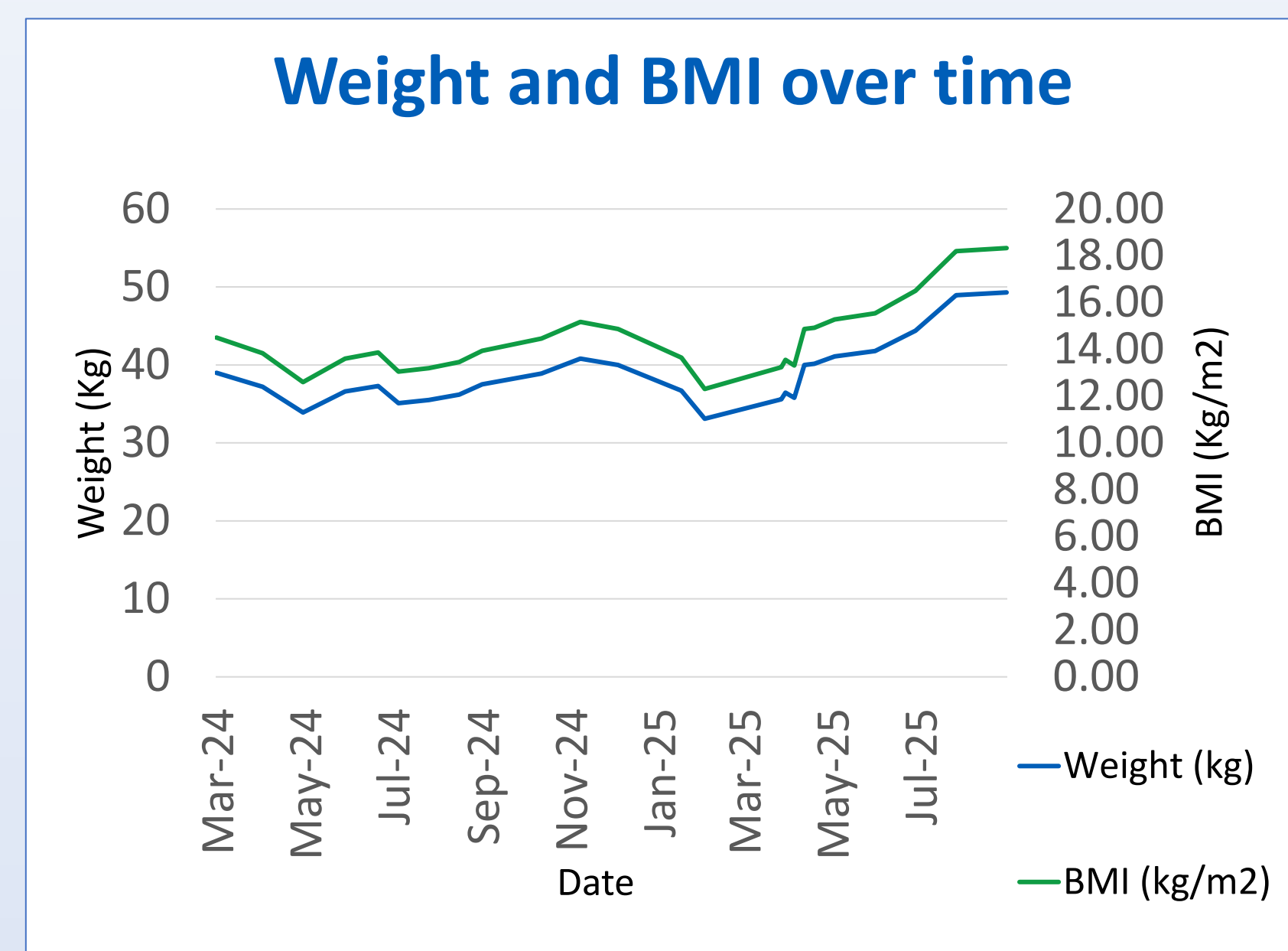
² St George's University Hospital's NHS Trust, London

Background

Transitions from acute care to specialist rehabilitation settings are challenging^{1,2}, carrying a high risk of poor outcomes and readmission. This complex case highlights the challenges across both settings, identified barriers and enablers to rehabilitation and nutrition and helped improve handovers supporting continuity of care.

A 62-year-old woman was admitted with collapse to a tertiary centre following a new diagnosis of advanced human immunodeficiency virus (HIV) (Viral load 8.25million CD4 11 [4.58%]), pneumocystis pneumonia (PCP), cytomegalovirus (CMV) and mycobacterium avium-intracellular (MAI).

Her 12-month acute admission required intensive input from the multidisciplinary team (MDT) including Dietitians, Physiotherapists and Occupational Therapists, enabling transfer to a specialist HIV rehabilitation hospital for six months of therapy before discharge. She was initially considered unsuitable for rehabilitation due to being bedbound with anticipated discharge to a nursing home. However, with sustained MDT intervention, she demonstrated significant functional improvement and was discharged home, mobilising independently with a stick.




Quote From Medical notes

"She doesn't have rehab potential.."

Month 18

CD4 180 VL 111
Independent walking with stick indoors and outdoors



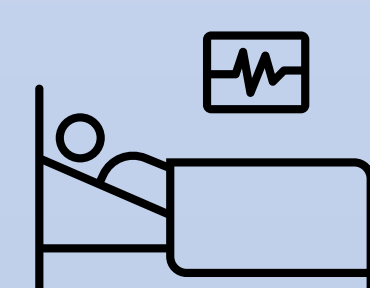
Month 12

CD4 198 VL 395
Sit on edge of bed with assistance of 1

Transfer to rehabilitation hospital

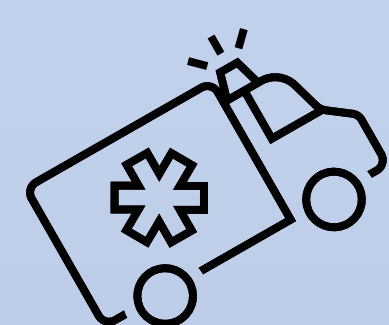
Month 6

CD4 175 VL 453
Hoist to chair with assistance of 2



Month 0

CD4 11 VL 8.25 million
Bedbound



Barriers to rehabilitation

Severe malnutrition and deconditioning requiring enteral and parenteral nutrition

Poorly motivated and institutionalised

Recurrent medical instability causing slow weight gain and inhibiting progress

Raised calcium and vitamin D levels due to MAI requiring adjustment of oral nutritional supplements

Menu fatigue and poor compliance with oral nutritional supplements

Enablers to rehabilitation

Holistic approach

Daily contact and rapport building

Rehabilitation diary and family support for motivation

Care within a specialist HIV service

Coordination across MDT with timely and thorough handover

Quote From the Patient post-rehab recovery

"Without your fantastic support, I wouldn't have got this far. I'm driving again, managing the steps to my flat, and getting my independence back. You've changed my life."

Recommendations

- People living with HIV that have complex rehabilitation needs should be cared for in a specialist service that understands their needs
- Timely and thorough handovers are crucial to enable continuity of care
- Continuous coordination across the MDT and between teams is important to optimise nutrition and rehabilitation
- A standardised handover tool may help to improve outcomes and ensure that all information is available
- Virtual MDT handovers can support complex transfers

Conclusion

This case emphasises the importance in rejecting early conclusions about rehab potential, instead adopting a flexible, patient centred approach grounded in long term specialist MDT involvement. A collaborative approach to care transitions provides opportunities for improved processes. This complex case reinforces the value of holistic, persistent multidisciplinary collaboration in patients with advanced HIV.

References

1. Cho S, Xi N, Bateman EA, Chui C, et al. (2025) Physician-physician handover from acute care to rehabilitation setting: A scoping review protocol. PLoS One 20(12): e0338916
2. O'Brien KK, Ibañez-Carrasco F, Solomon P, et al. (2014) Advancing research and practice in HIV and rehabilitation: a framework of research priorities in HIV, disability and rehabilitation. BMC Infect Dis. 14:724